

January 1, 2008

Volume 1 Issue 8

PAWS TO THE STARS

Dental Care of Ferrets

Ferrets should have their teeth professionally cleaned to remove plaque and tartar, and prevent early periodontal disease and loss of teeth. Ferrets fed a soft diet are more likely to have a significant build-up of plaque and tartar (calculus) on the teeth than those fed a dry pelleted ration. Check your ferret's teeth regularly, especially the canine teeth and upper molars, to see how much plaque has accumulated.

Professional care

Oral Exams by Your Veterinarian: A thorough dental exam can identify potential problems such as plaque and tartar build-up, gingivitis, periodontal disease, and fractured or abscessed teeth. During an oral exam your veterinarian will:

Examine the face and head for asymmetry, swelling, or discharges.

Examine the outside surfaces of teeth and gums, and the "bite".

Open the mouth to examine the inner surfaces of the teeth and gums and the tongue, palates, oral mucosa, tonsils, and ventral tongue area.

Dental Cleaning by Your Veterinarian: If your ferret's teeth have tartar, it is necessary for your veterinarian to remove it and polish the teeth. This professional veterinary dental cleaning is also called a prophylaxis or "prophy." A routine dental cleaning consists of:

Table of Contents

Dental Care of Ferrets PP. 1-2


Dental Anatomy and Dental Care of Rabbits and Rodents PP.3-5

Dental Disease and Common Oral Conditions in Rabbits and Rodents PP.6-8

Bird Beaks : Anatomy, Care and Diseases PP.9-15

Contact Information P. 16

Care for Rabbits and Rodents



Dental Care of Ferrets



A chameleon



Parakeet

Anesthetizing your ferret and flushing the mouth with a solution to kill the bacteria.

Cleaning the teeth with handheld and ultrasonic scalers. All calculus is removed from above and below the gumline.

Using a disclosing solution to show any areas of remaining calculus which are then removed.

Polishing the teeth to remove microscopic scratches.

Inspecting each tooth and the gum around it for any signs of disease.

Flushing the mouth, again, with an antibacterial solution.

Recording any abnormalities or additional procedures on a dental chart.

Determining the best follow-up for your ferret.

Professional dental cleaning may have to be done once or twice a year in older ferrets, depending on the condition of the teeth and the diet.

Dental Anatomy and Dental Care for Rabbits and Rodents

Dental Anatomy and Dental Care for Rabbits and Rodents

Veterinary and Aquatic Service Department Drs. Foster & Smith"


Lagomorphs" (the most popular lagomorph pet is the rabbit) and rodents share some similar dental features although there are differences. Lagomorphs are distinguishable from rodents in that they have two pairs of upper incisors (the second pair, located immediately behind the larger incisors, are small and peg shaped, often referred to as the "peg teeth"); rodents have one pair. Lagomorphs also have more teeth than rodents (specifically, premolars) and their lower jaw (called the "mandible") is narrower than the upper jaw (called the "maxilla"), while in rodents, the upper jaw is narrower than the lower jaw.

Lagomorphs, like cats, dogs, and humans, are "diphyodont" meaning they have two sets of teeth, one set (called "deciduous", or "baby teeth") being shed and replaced by a permanent set. However, in lagomorphs, the deciduous teeth are rarely seen as they are generally shed before birth or shortly thereafter. Rodents have only one set of teeth their entire lives. The incisors of both lagomorphs and rodents are "aradicular hypsodont" (they have no anatomical root), therefore, they continually grow throughout life. Lagomorphs have a white incisor enamel color while rodents have a yellow incisor enamel color.



A Tribble

A Good Tip:
When you are in deep trouble, look straight ahead, keep your mouth shut, and say nothing.



Dental Anatomy and Dental Care for Rabbits and Rodents

Lagomorphs and the truly herbivorous rodents (such as the chinchilla and guinea pig) feed on tough, fibrous vegetation in their natural environment; other rodents, such as hamsters, rats, and mice feed mainly on tubers (a fleshy, underground part of a plant, such as a potato), seeds, and grain. In the true herbivores, the diet tends to have a low energy content requiring the intake of larger quantities of food, resulting in more grinding of the vegetation and rapid wear to the cheek teeth (large teeth in the back of the mouth used for grinding). As a result, the cheek teeth, like the incisors, have evolved to continuously grow throughout life. In other rodents, the diet of tubers, seeds, and grain requires little chewing, resulting in little wear of the cheek teeth. As a result, these cheek teeth have anatomical roots and stop growing once they have fully erupted.

Malocclusion" refers to an undesirable alignment of upper and lower teeth when the jaw is closed. Malocclusion can occur due to several reasons including genetics, trauma to the teeth, abnormal growth, reverse scissor bite, and, most commonly, inappropriate diet. Malocclusion can occur in the cheek teeth and the incisors, resulting in the uneven wear of the teeth and often the overgrowth of the teeth. If overgrowth occurs, the teeth can be trimmed by a veterinarian to prevent further problems.

Dental and oral care

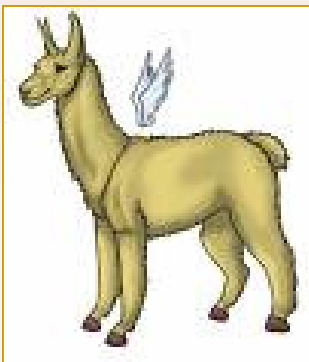In the truly herbivorous lagomorphs and rodents, a diet consisting of tough, fibrous roughage is extremely important to the health of the animal. If a diet that does not require enough chewing is given, cheek tooth wear is uneven causing spikes of enamel to grow on the outer and inner sides of the teeth. These spikes can cause severe oral pain resulting in excessive salivation (often called "slobbers"), reluctance to chew, inability to close the mouth, and reduced food intake. The situation deteriorates as the teeth continue to grow, and, if it is not treated, will result in severe malnutrition.

Dental Anatomy and Dental Care for Rabbits and Rodents



A Stuffed Penguin

If you can donate time or money to a no kill dog or cat shelter



Virtual pet Wooley Hooves

In some species, cheek tooth overgrowth can lead to root elongation. When this occurs the root continues to grow through the oral tissues causing swellings. If this occurs in the upper jaw, the root can grow to the point of affecting the eyes, resulting in watering, bulging, or inflammation.

Because there are limited treatments in lagomorph and rodent dental disorders, prevention is best. The teeth should be examined routinely for abnormalities and a balanced diet enriched with coarse vegetation should be fed to maintain adequate wear. Contact your veterinarian if you see abnormal growth or if your pet drools, has difficulty chewing, is eating less, or shows pain when touched around the mouth or head. If diagnosed early, the enamel points and/or overgrown incisors can be trimmed by the veterinarian. In more severe cases, permanent damage may have already occurred.

It is important to know, especially in the differing rodents, the anatomy and physiology of the teeth so appropriate care and nutrition can be provided for a long and healthy life.

References and Further Reading

Crossley, D. Clinical Aspects of Lagomorph Dental Anatomy: The Rabbit (*Oryctolagus cuniculus*). *Journal of Veterinary Dentistry*, Vol. 12 No. 4; 1995: 137-140.

Crossley, D. Clinical Aspects of Rodent Dental Anatomy. *Journal of Veterinary Dentistry*, Vol. 12 No. 4; 1995: 131-135.

Dental Disease and Common Oral Conditions in Rabbits and Rodents

Veterinary Services Department, Drs. Foster & Smith, Inc

Overgrown incisors

The incisors of rabbits and rodents continue to grow throughout their lifetime. The constant gnawing that should normally occur continually wears the teeth down. If the top and bottom incisors do not oppose (meet correctly), however, one or more of the teeth may overgrow. If this occurs, the affected incisor will need to be trimmed.


Overgrown cheek teeth and slobbers

In rabbits and many rodents, the cheek teeth (teeth toward the back of the mouth) also continue to grow throughout the life of the animal. A diet consisting of tough, fibrous roughage is necessary to wear down the teeth. If a diet that does not require enough chewing is given, cheek tooth wear is uneven causing spikes of enamel to grow on the outer and inner sides of the teeth.

These spikes can cause severe oral pain resulting in excessive salivation (often called "slobbers"), reluctance to chew, inability to close the mouth, and reduced food intake. The situation deteriorates as the teeth continue to grow, and, if it is not treated, will result in severe malnutrition.

Root elongation

In some species, the roots of overgrown teeth may also elongate. When this occurs the root continues to grow through the oral tissues and can cause swellings. If this occurs in the cheek teeth of the upper jaw, the root can grow



TURTLE


Dogs have owners

Cats have staff

Anonymous



A green iguana



**"We
can
judge
the
heart
of a
man by
his
treat-
ment
of ani-
mals."
~ Im-
manua**



Dental Disease and Common Oral Conditions in Rabbits and Rodents

to the point of affecting the sinuses or the eye. This can result in drainage from the nose, discharge from the eye, or watering or bulging of the eye. When root elongation occurs in the lower jaw, it usually results in a large firm swelling.

Fractured teeth

The incisors (front teeth) of rabbits and rodents can occasionally fracture. This most commonly results from the animal chewing on or getting his teeth caught in the metal of a cage. Radiographs (x-rays) may need to be taken to determine how much of the tooth is involved. If the pulp of the tooth is exposed, the condition can be very painful. If this occurs, a veterinary dentist can remove part of the pulp and a temporary cap can be placed on the tooth. Since incisors continue to grow, the tooth normally coming into contact with the broken tooth may overgrow, and may need to be trimmed periodically. If the root of the tooth was not affected, and infection does not occur, the broken incisor will usually regrow. Sometimes the regrowing tooth is deformed and will need to be trimmed regularly.

Cheek pouch disorders in hamsters

Hamsters have large cheek pouches in which they can temporarily store food. There are several disorders that can involve these pouches.

Everted cheek pouches: For unknown reasons, in some hamsters, the cheek pouches may evert (turn inside out). The pouch appears as a pink, moist mass coming out of the corner of the mouth. A veterinarian can anesthetize the hamster, return the pouch to its normal position, and

Dental Disease and Common Oral Conditions in Rabbits and Rodents

then place a suture (stitch) to keep it in place. A small amount of scar tissue will build up around the suture. This will help to keep the pouch in place after the suture is removed in about 2 weeks.

Impacted cheek pouches: In some cases, food may become impacted (tightly wedged) in the cheek pouch. This will appear as a large persistent swelling of the cheek. Under anesthesia, a veterinarian can remove the impacted food and flush out the pouch. The area will be examined to determine the reason for the impaction (e.g., an over-



RED MCCA

Bird Beaks: Anatomy, Care, and Diseases

Veterinary & Aquatic Services Department, Drs. Foster & Smith

A bird's beak, also called the "rostrum," is used for many things from a weapon for enemies, to grooming, to the delicate feeding of a nestling. Beaks can be a combination of strength and sensitivity, strong enough to crack a walnut yet delicate enough to peel a grape.

Anatomy

A bird, like a mammal, has two jaws: the upper is the maxilla and the lower is the mandible. The nostrils, or nares, are located at the junction between the beak and the head. In most parrots, a small, round, brown structure, called the operculum is found inside of the nostril. This is comprised of cartilage and should not be mistaken for an obstruction or foreign body, such as a seed. Some species of birds, such as the parrots, have an area of fleshy tissue that contains the nares. This is called the cere. In budgies, the cere is blue in adult males, and a pinkish brown in females.

The beak is comprised of the jaw bone covered with a lightweight sheath called the rhamphotheca. The rhamphotheca is made of keratin, which is the same substance found in antlers or our fingernails. And like horns or fingernails, the beak is constantly growing. Depending upon the species, a bird's beak grows from one to three inches a year. The portion of the rhamphotheca covering the maxilla is called the rhinotheca, and that covering the mandible is the gnathotheca.

The proximal (closest to the bird) portion of the beak has a blood supply and a significant number of nerve endings. The distal portion (toward the tip) of the beak, like the end of a fingernail, does not sense pain.

Some parrots have file-like ridges crossing the inside of the upper bill. These aid the bird in cracking nuts and hard fruits.

There is a great variation in the size, shape, and strength of beaks. The type of beak a bird has is usually related to the type of food the bird normally eats

Strong, hook-like beaks, such as those on toucans and parrots, can crack an outer shell of a nut or the tough outer skins of certain fruits.

Bird Beaks: Anatomy, Care, and Diseases

Short, straight bills are perfect for seed and grub eaters. These include finches and canaries.

Nectar-eating birds, such as hummingbirds, have long, pointed beaks for reaching into the heart of a flower.

Wild birds, such as woodpeckers, have extremely strong, chisel-like beaks.

Water birds, such as cranes, may have long beaks for probing; birds such as ducks and flamingos have flat beaks with special plates called lamellae, which help filter food.

Raptors have hook-like beaks used for tearing food.

Insect-eating birds, such as warblers, have short beaks.

Some birds, such as swifts, have wide mouths, for catching insects while flying.

A healthy bird has a healthy beak. And a healthy beak means that your bird will be using it to eat, play, and chew. If your bird's beak is causing him discomfort in some way, he will avoid using it. Signs that your bird's beak is in healthy include:

Smooth, symmetrical appearance

No peeling or unusual textures (Members of the cockatoo family should have fine powder on their beaks, the result of proper grooming of healthy feathers. See Feather Types, Anatomy, and Molting)

No discolored areas

Proper beak length (Check with your regular avian veterinarian to see if the tip of your bird's beak is as short as it should be for her particular species).

Proper alignment of the upper beak and lower beak

Abnormal beak growth and development

Bird Beaks: Anatomy, Care, and Diseases

The most common beak abnormalities include:

Overgrown beak

Scissors beak

Prognathism or "parrot beak"

Overgrown beak: Either the upper or lower beak may overgrow, though it is far more common for the upper beak to do so. For some normal birds, regular beak trimming is necessary. Other birds may keep their beaks in proper form through eating a hard diet, grooming, climbing, chewing on toys, and rubbing the beak on a slightly abrasive surface. An overgrown beak can be the result of health problems including trauma, developmental abnormalities, nutritional imbalances, polyomavirus-like infection (finches), or liver disease (especially in budgies). See table below.

Treatment consists of trimming the beak to the proper shape and removing any excessive flaking. An overgrown beak is similar to an overgrown fingernail in that the overgrown portion has no sense of pain. The overgrown portion may be safely trimmed back to normal length without causing discomfort to the bird. Beak trimming is best performed by a veterinarian, unless you have considerable experience. If a beak is trimmed too short, it will cause the bird pain, will bleed, and may make it difficult or impossible for a bird to eat. Beak trimming may be performed using manual tools, such as human fingernail clippers and nail files, or side-cutting wire cutters. Some veterinarians prefer to use a Dremel drill grinding stone. In either case, the bird is generally not anesthetized for the procedure.

Scissors beak: Scissors beak is a lateral deviation of the rhinotheca. It is a developmental abnormality that occurs most commonly in cockatoos and macaws. It is thought to be caused by improper temperature during artificial incubation, genetics, or incorrect feeding techniques. Other possible causes include calcium deficiency, trauma, or a viral or mycobacterial infection.

Bird Beaks: Anatomy, Care, and Diseases



Parrot



A bicolor parrot fish

Treatment varies with the severity of the problem and the age of the bird. In young birds with mild deviations, simply applying finger pressure to the appropriate side of the beak for several minutes 2-3 times daily, may correct the problem. In older birds, or those with more severe deviations, an avian veterinarian may need to perform surgery and apply a type of acrylic prosthesis (splint) to correct the abnormal growth.

Prognathism or "Parrot Beak:" Mandibular prognathism occurs when the tip of the rhinotheca rests on or inside the gnathotheca. This developmental abnormality is most commonly seen in cockatoos. The cause of this condition is unknown, and may include genetics, improper incubation, and hand-feeding techniques. It is rarely seen in parent raised birds. It is thought that when parent birds hook onto the chick's rhinotheca during feeding, they help to promote the normal development of the chick's beak.

As with scissors beak, treatment varies with the severity of the condition and the age of the bird. For some chicks, applying finger pressure several times daily may help, as will using a piece of gauze to apply traction to the upper beak during feeding. In an older bird, in which the beak has calcified, treatment generally involves the placement of an acrylic appliance on the beak. The type of appliance varies depending upon the extent of the problem.

home beak care

Beak care is critical for the overall health of the bird. The beak is the entry for nutrients, and is used for climbing and playing. We can help promote beak health by ensuring the bird is getting all the nutrients he needs and detecting any problems early. Some at-home care includes:

Bird Beaks: Anatomy, Care, and Diseases

Daily checking the health of your bird. Look for cracks, overgrowth, or discoloration of the beak.

Consulting an avian veterinarian if you suspect that your bird's beak is growing unevenly. This can indicate underlying problems such as liver or nutritional issues. Your avian veterinarian can determine the reason for the problem as well as trim it to prevent problems with eating or preening.

Providing chewing toys, any toy that a bird has to work at chewing will help keep his beak trim. These include build-your-own toys that you can make by alternating mineral pieces with rope, wooden, blocks, and plastic.

Including different textures of perches, including cement perches specifically made for beak and nail health. Note: Do not use sandpaper perches.

Housing the bird in a proper size cage. Owners of large parrots, especially, need to provide a sturdy cage. Parrot owners we know have come home to a flimsy cage with snapped bars and the soldering (made of toxic lead and zinc in some inexpensive cages) chewed off.


Trauma

Trauma to the beak may occur as the result of fighting, chewing on electric cords, hitting the beak while flying or landing, or having the beak trapped between cage bars or other hard surfaces. Injuries may include fractures, punctures, and avulsions (tearing away of the beak). Injuries to the beak often bleed, and the hemorrhage needs to be stopped (usually with electrocautery).

DO NOT use silver nitrate sticks - they are toxic to birds).



Pot Belly Pig



A Sugar Glider



Bird Beaks: Anatomy, Care, and Diseases

The wounds must be cleaned and antibiotics and antifungals may need to be given. The beak has nerve endings, and pain or the displacement of the beak may make eating difficult or impossible. All birds with beak injuries should be examined by a veterinarian. Acrylics may be used to repair the beak until new tissue replaces it.

Common Beak Lesions Common Beak Lesions Common Beak Lesions

Lesion	Possible Cause	Species
Abnormal growth	Liver disease	
Knemidocoptes mites		
Polyomavirus-like infection		
Psittacine Beak and Feather Disease (Pbfd)		
Vitamin D3 deficiency		
Soft food		
Malnutrition		
Old trauma	Budgies	
Budgies		
Finches		
Shiny surface to beak (instead of powdery appearance)		Pbfd Cockatoos
Crusty lesions	Avian Pox	
Knemidocoptes mites		
Bacterial infection	Amazon parrots	
Budgies		
Soft, pliable beak ("rubber beak")	Calcium or Vitamin D deficiency	Cockatiels
Discoloration	Malnutrition or systemic disease	Toucans and Lorikeets
White lesions in mouth, excess mucus, swelling	Candida infection	
Trichomonas infection		
Bacterial infection		
Vitamin A deficiency		

Bird Beaks: Anatomy, Care, and Diseases

Sunken, irregular lesions Old trauma

Aspergillus infection

Candida infection

Bacterial infection

PBFD

Ulcerative lesions at beak junction Avian Pox

Trichomonas Cockatiels

References and Further Reading

Boussarie, D. Anomalies and disorders in beak and feathers. World Small Animal Veterinary Association 2002 Congress Proceedings, Granada, October 3-6, 2002.

Clipsham, R. Beak repair: Rhamphorthotics. Altman, RB; Clubb, SL; Dorrestein, GM; Quesenberry, K. (eds.) Avian Medicine and Surgery. W.B. Saunders Co. Philadelphia, PA; 1997.

Olsen, GH; Orosz, SE. Manual of Avian Medicine. Mosby, Inc. St. Louis, MO; 2000.

Rupley, AE. Manual of Avian Practice. W.B. Saunders Co. Philadelphia, PA; 1997.

Contact information

Capt. Marie Anderson

USS Liberator

Chair of Commutations –USS Liberator

Director of Communications –Petfleet

TeamSummit

Moderator SFI—L

Mande64911@roadrunner.com

11118 Clifton C309

Cleveland, OH 44102

Vegan Diet?

If you are putting in an application for a certificate for your pet or putting your pet's name on the Memory Page, Please send all monies to:

Captain John Schulte

**Vice Regional Coordinator Sixth Fleet/Chief Financial Officer,
PetFleet**

Coordinator

CO, USS Riverside NCC 1660

**Home ported at the future birthplace of Captain James T. Kirk,
Riverside**

Iowa.

www.ussriverside.us

LiveJournal: http://sixth_fleet_vrc.livejournal.com

YM: starfleetofficer2

IMVU: JSchulte

Make checks payable to John Schulte